

The development of chicken cerebellar cortex and the determination of AgNOR activity of the Purkinje cell nuclei

Serdar Akar & Emrah Sur*

Department of Histology and Embryology, Faculty of Veterinary Medicine, University of Selcuk Campus, 42003, Konya, Turkey

* Corresponding author: emrahsur41@hotmail.com

ABSTRACT. In this study, the embryonic and post-hatching development of the chicken cerebellar cortex, and the number, size and area of the silver-staining nucleolus-organizer regions (AgNORs) were determined in cerebellar Purkinje cells in layer-hen (Babcock-B380) embryos and chickens. The mean transverse diameter of the Purkinje cells and their nuclei, and the mean area of the Purkinje cell nucleus and AgNOR area increased during the entire experimental period. The mean ratio of the AgNOR area to the Purkinje cell nucleus area reached its highest value at the 15th day of incubation. There was no difference between the mean AgNOR numbers per nucleus. These findings provide reference data for future studies in this and related research topics, for example for establishing AgNOR parameters and we also hope that our data will be supplemented with other techniques such as PCNA and TUNEL in the near future.

KEY WORDS: KEY WORDS: AgNOR, Cerebellum, Purkinje cell.

INTRODUCTION

The cerebellum is an important organ, both because its dysfunction leads to pronounced disturbances in movement, posture and balance and because it is a relatively massive structure in higher vertebrates. In humans, it represents about 10% of the volume of the brain, and even more striking, it has been estimated to hold more than half of all the neurones in the central nervous system (MIAL & RECKESS, 2002).

The cerebellum develops from the dorso-lateral part of the alar plates of the metencephalon (NICKEL et al., 1977; MIAL & RECKESS, 2002). FEIRABEND (1990) first observed that the cerebellum develops from the neuro-epithelium of the dorsal part of the 4th ventricle and recognized the constriction, called "isthmus", formed between mesencephalon and rhombencephalon at the 4th day of incubation in chicken embryos.

Similarly to in mammalian species, the cerebellar cortex in avian species also arises from two different germinal zones called the ventricular germinal zone (VZ) and the external granular layer (EGL) (ESPINAR et al., 1997). According to FEIRABEND et al. (1985), the cerebellar mantle layer arises from the ventricular neuro-epithelium and soon becomes subdivided into an inner (IML) and outer mantle layer (OML) at the early (4-8th day of incubation) embryonic period. The OML subdivides into the deep (OML-d) and superficial (OML-s) parts. The OML-d develops into the central cerebellar nuclei whereas the OML-s develops into the EGL. The inner cortical layer, which gives rise to the future Purkinje cells, is derived from the IML.

Purkinje cells, unique neurons in the central nervous system, originate from the VZ. These cells are the largest neuronal cell type in the cerebellar cortex and have the most elaborate synaptic interactions in the cerebellum (LEE et al., 2001). The myelinated axons of the Purkinje

cells terminate on neurons of the cerebellar nuclei and certain brainstem nuclei (NICKEL et al., 1977; VOOGD & GLICKSTEIN, 1998; LEE et al., 2005). Because the Purkinje cells establish morpho-functional and synaptic connections, that demand high metabolic activity, they synthesize different amounts of protein at different developmental stages during the embryonic period (BERTOSI et al., 1986).

Nucleolar-organizer regions (NORs) are loops of DNA containing ribosomal RNA genes (ROBERT-FORTELE et al., 1993). These regions can be easily stained with silver methods to appear as black dots (AgNORs) in the cell nucleus since they are argyrophilic. NORs are used by cytogeneticists for studying chromosomal disorders. This staining technique is very simple and does not require any special instruments or costly reagents (KHANNA et al., 2005). Additionally, the size, number and dispersion of the silver deposits on the NOR reflect the degree of transcriptional, nucleolar and proliferative activity of the cells (SUR et al., 2003; BUKHARI et al., 2007).

The nervous system is extremely sensitive to several factors that could affect the developing embryo. The cerebellum is often chosen for experimental studies on central nervous systems because of its well-defined cytoarchitecture and pathways of cerebellar cell migration during neurogenesis (FULTS et al., 1985). The chicken embryo has proven to be one of the most valuable study objects for developmental biology, providing several advantages: eggs are easy to obtain; the development of the embryo is well known; the development takes places outside of the maternal organism and is thus easily accessible for experimentation and observation on subsequent development (KUCERA & BURNAND, 1987). Because of their independent development from any maternal influence, chicken embryos also facilitate specific experimental manipulation, whereas determining the effects of teratogenic or an embryotoxic chemicals agent on the central nervous system of mammals is very difficult because of the placenta

(JELINEK et al., 1985). Here, we investigated the embryonic and post-hatching development of the chicken cerebellum and determined some AgNORs parameters of Purkinje cells, a cell type used as a model in similar studies, to obtain basic data for further studies on this system and related research.

MATERIALS AND METHODS

Materials

Animals

For the experiment, 100 fertilized eggs of laying hens (Babcock B-380) were used. Eggs were fumigated (80g potassium permanganate in 130mL 40% formaldehyde solution per m³ for 20min) and subsequently placed in an incubator, at 37°C and 65% humidity.

Methods

Histological investigations

On the 7th, 9th, 11th, 13th, 15th and 18th days of incubation, six randomly-selected whole embryos were fixed in buffered 10% formal-saline solution (pH 7.4) for a week, dehydrated in alcohol, cleared in xylene and embedded in paraffin blocks. On the day of hatching, subsequent 10th day, 3rd week and 4th week post hatching, six randomly-selected chickens were decapitated. The cerebellum was removed and tissue samples processed according to the histological methods mentioned above. For routine histological examinations, tissue sections of 4–6µm taken from paraffin blocks were stained with Crossman's trichrome staining and hematoxylin & eosin staining (CULLING et al., 1985).

Staining the AgNORs

From the 11th day of incubation onward, tissue sections were stained with a solution containing one volume of 2% gelatine in 1% aqueous formic acid and two volumes of 50% silver nitrate (Merck). The staining was performed at 37°C in the dark for 20–30 minutes (AYDIN & CELIK, 2005).

The histological preparations were examined with a light microscope (Leica DM-2500 attached to a DFC-320 digital camera). In each cerebellum of an embryo or chicken, 25 Purkinje cells having nuclei were analyzed. The transverse diameter of Purkinje cells and of their nuclei, the nuclear area, the AgNOR area and AgNOR counts were analysed with an image analysis programme (IM-50). Also, the percentage of the AgNOR area relative to the whole nuclear area was calculated.

Statistical analyses

All statistical analyses, in particular ANOVA and DUNCAN tests, were conducted with the Statistical Package for the Social Sciences (SPSS 9.0, SPSS Inc. Corp. Chicago, IL., USA) (TEKIN, 2003).

RESULTS

Embryonic development of the Cerebellum

On the 7th day of incubation, the cerebellum developed from the dorsal metencephalic region at the roof of the fourth ventricle. In this stage, the cerebellar anlage consisted of ventricular neuroepithelium lining the ventricle lumen, inner mantle layer and outer mantle layer (Fig. 1). On the 9th day of incubation, the inner cortical layer, which would give rise to the future Purkinje cells, was recognized at the superficial part of the inner mantle layer (Fig. 2). On the same day, cell accumulation was distinct in the superficial part of the outer mantle layer, called "external granular layer (EGL)" (Fig. 2). At the same incubation period, the dark granule cell groups (granule cell raphe) that migrate from the EGL to the inner granular layer were observed in the marginal layer, localized beneath the EGL (Fig. 2). On the 11th day of incubation, the cerebellar folia were observed for the first time, following advanced fissuration of the cerebellar cortex (Fig. 3). Purkinje cells appeared arranged as small clusters beneath the marginal layer. In the cerebellum of a 13-day-old embryo, all nine primary folia were recognizable and a secondary foliation was just beginning in folium V (Fig. 4). Also by the 13th day of incubation, the marginal layer had increased in thickness, whereas the primitive cortex consisted of an external granular layer. A primitive molecular layer, an inner cortical layer and an inner granular layer were very distinct by the 15th day of incubation, at which time the Purkinje cells appeared to be arranged in one or two rows (Fig. 5). By the 18th day of incubation, the molecular layer and the inner granular layer had increased in thickness whereas the inner cortical layer had decreased in thickness. The Purkinje cells were arrayed in a manner similar to that in adult cerebellum (Fig. 6).

Post-hatching development of the Cerebellum

The cerebellar cortex completed its development and the Purkinje cells were then typically located in a single row at the border of the granular and molecular layer by the day of hatching. However, our observations revealed that the EGL gradually decreased in thickness during the four weeks after hatching (Fig. 7).

AgNORs parameters of the Purkinje cells

In general, AgNORs were observed as black patches having irregular shapes in the cell nuclei (Fig. 8). Although AgNORs were identified by the 9th day of incubation, they were too small to be measured reliably before the 11th day of incubation. The mean transverse diameter of the Purkinje cells and their nuclei, the mean area of the Purkinje cell nucleus and the AgNOR area increased through the entire experimental period. The mean percentage of AgNOR area relative to Purkinje cell nucleus area reached its highest value at the 15th day of incubation (25±3.80%). There were no differences between the AgNOR counts on different days (Table 1).

TABLE 1
AgNORs parameters of the Purkinje cells

Time	Mean transverse diameter of Purkinje cell bodies \pm SE (μ m)	Mean transverse diameter of Purkinje cell nuclei \pm SE (μ m)	Mean Purkinje cell nucleus area (μ m ²) \pm SE	Mean AgNOR area(μ m ²) \pm SE	Relative (%) AgNOR area \pm SE	Mean AgNOR number per nucleus \pm SE
11 th incubation day	4.77 \pm 0.09 ^a	3.34 \pm 0.03 ^a	10.02 \pm 0.11 ^a	1.96 \pm 0.2 ^a	19 \pm 2.12 ^a	1.48 \pm 0.06 ^a
13 th incubation day	5.25 \pm 0.07 ^a	3.55 \pm 0.09 ^a	11.60 \pm 0.38 ^a	2.64 \pm 0.44 ^a	20 \pm 1.96 ^a	1.52 \pm 0.08 ^a
15 th incubation day	7.58 \pm 0.11 ^b	4.23 \pm 0.07 ^b	17.17 \pm 0.51 ^b	4.45 \pm 0.63 ^b	25 \pm 3.80 ^b	1.46 \pm 0.11 ^a
18 th incubation day	10.69 \pm 0.38 ^c	5.44 \pm 0.18 ^c	25.99 \pm 2.1 ^c	4.77 \pm 0.49 ^b	17 \pm 5.42 ^a	1.54 \pm 0.03 ^a
Day of hatching	11.77 \pm 0.15 ^d	5.59 \pm 0.04 ^c	32.44 \pm 0.81 ^d	2.25 \pm 0.17 ^a	6.5 \pm 4.28 ^c	1.37 \pm 0.04 ^a
10 th day post-hatch	15.85 \pm 0.55 ^e	8.04 \pm 0.26 ^d	61.87 \pm 3.6 ^e	4.67 \pm 0.26 ^b	7.1 \pm 3.07 ^c	1.35 \pm 0.04 ^a
3 rd week of post-hatch	17.75 \pm 0.33 ^f	8.96 \pm 0.15 ^e	70.65 \pm 1.7 ^f	5.94 \pm 0.68 ^{bc}	8 \pm 1.12 ^c	1.54 \pm 0.06 ^a
4 th week of post-hatch	18.46 \pm 0.44 ^f	9.10 \pm 0.18 ^e	69.38 \pm 1.9 ^f	7.19 \pm 0.84 ^c	10 \pm 1.52 ^c	1.37 \pm 0.06 ^a

a–f Values within a column with no common superscripts are significantly ($P < 0.05$) different.

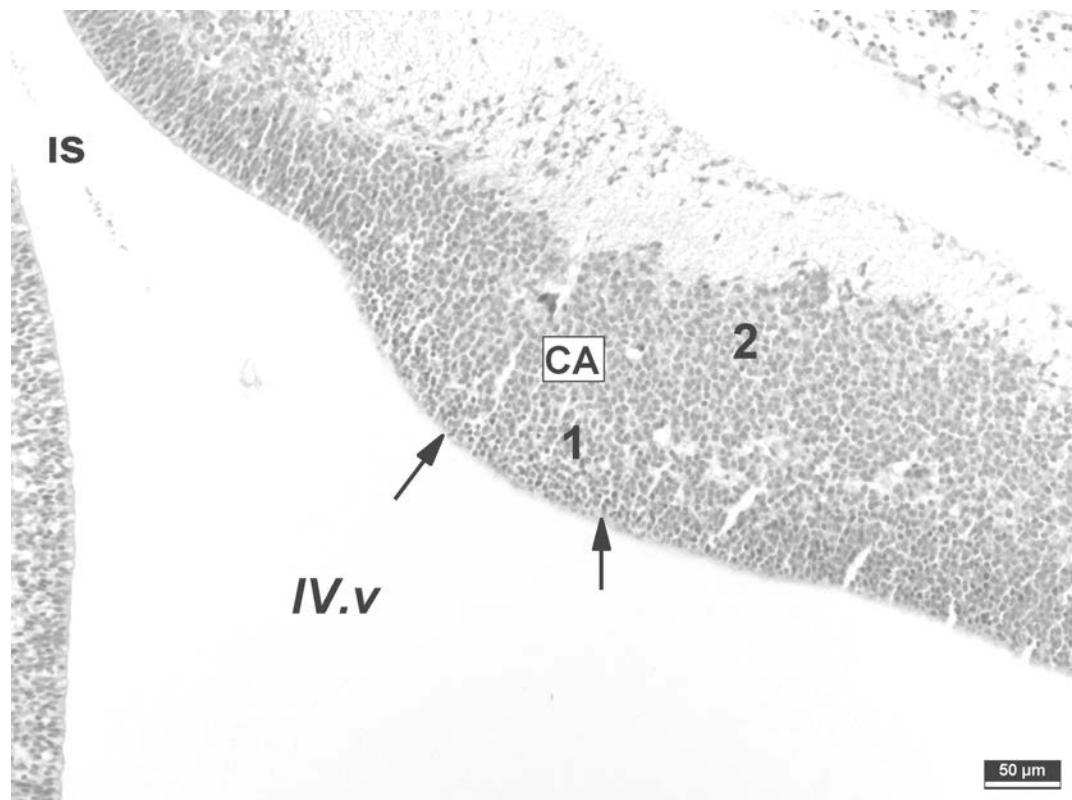


Fig. 1. – A section from the developing cerebellar primordium of chicken embryo on day 7 of incubation. CA: Cerebellar anlage, IS: Isthmus, IV. v: Fourth ventricle, 1: Inner mantle layer, 2: Outer mantle layer, Arrows: Ventricular neuroepithelium. Hematoxyline and Eosin staining.

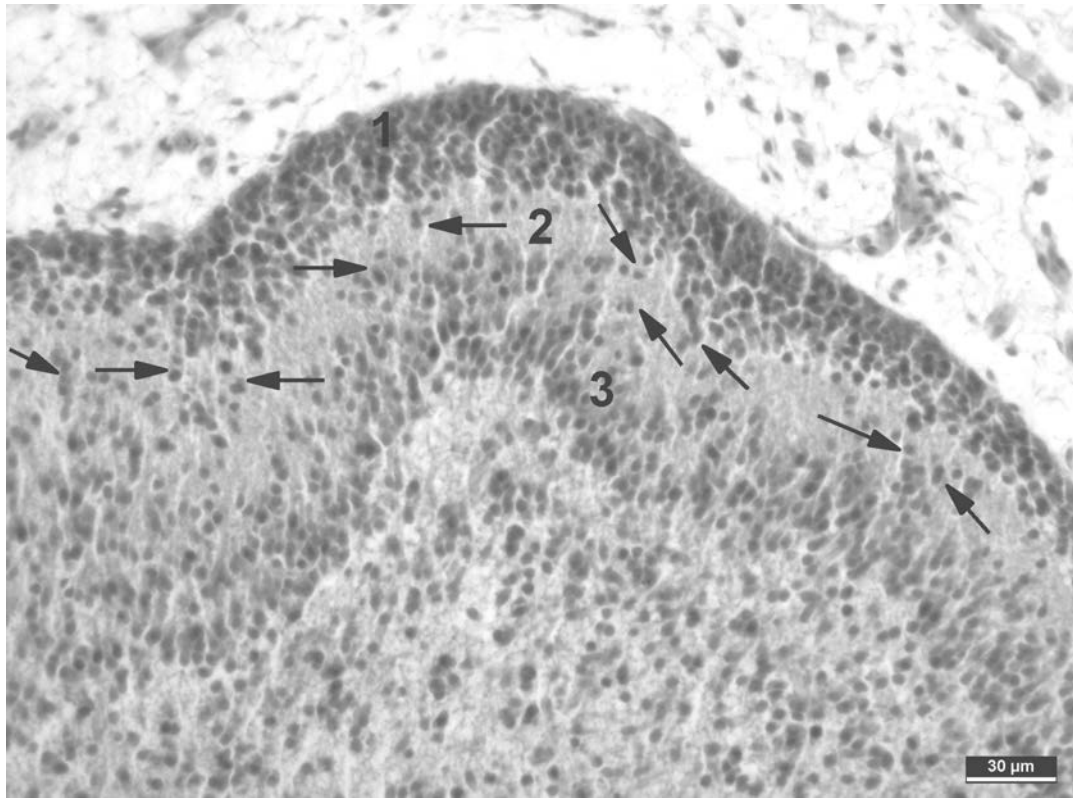


Fig. 2. – A section from the developing cerebellar primordium of chicken embryo on the 9th day of incubation. 1: External granular layer (EGL), 2: Marginal layer, 3: Inner cortical layer, Arrows: Granule cells migrating from EGL to the internal granular layer. Trichrome staining.

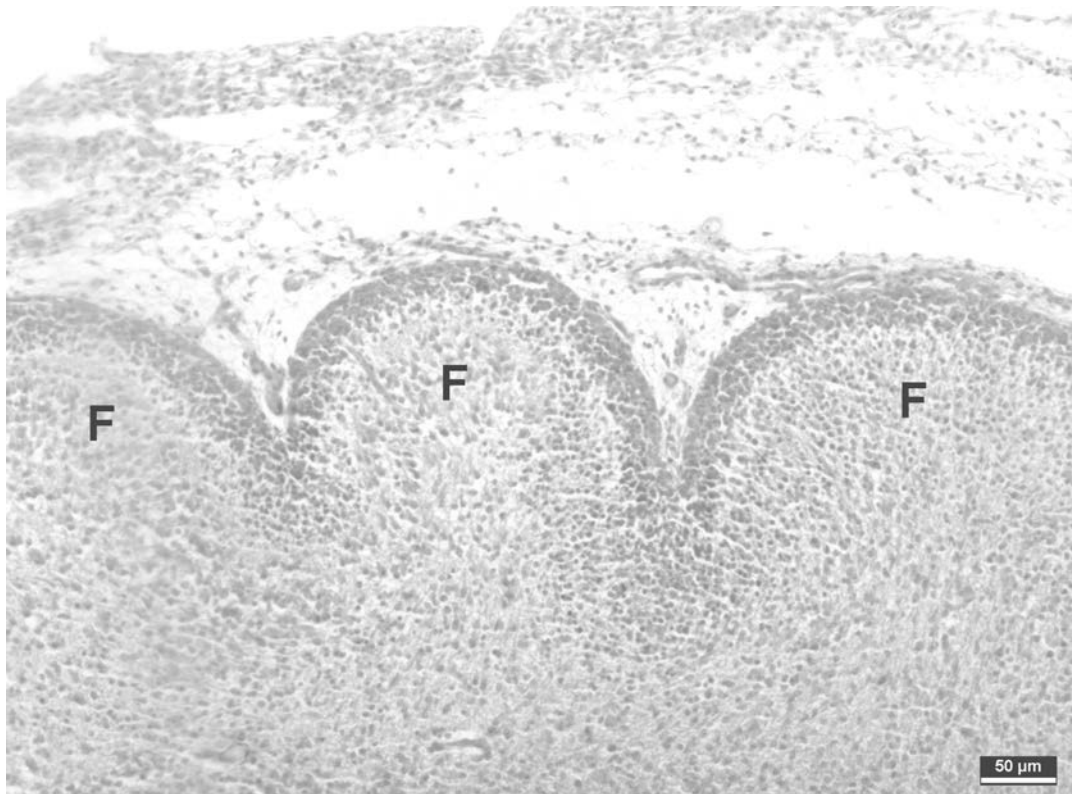


Fig. 3. – A section from the developing cerebellum of chicken embryo on day 11 of incubation. F: Cerebellar folia. Trichrome staining.

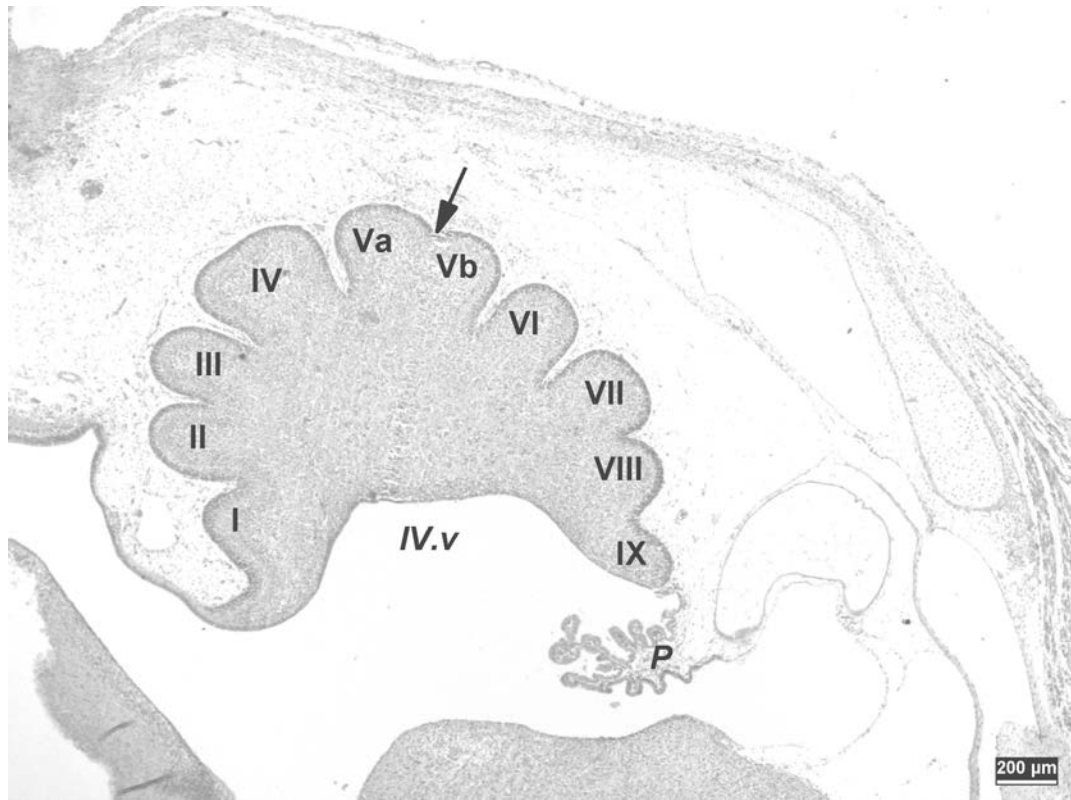


Fig. 4. – A section from the developing cerebellum of chicken embryo on day 13 of incubation. All 9 primary folia are distinct. I-IX: Primary folia, a, b: Secondary folia, Arrow: Secondary foliation, P: Plexus choroideus, IV.v: Fourth ventricle. Trichrome staining.

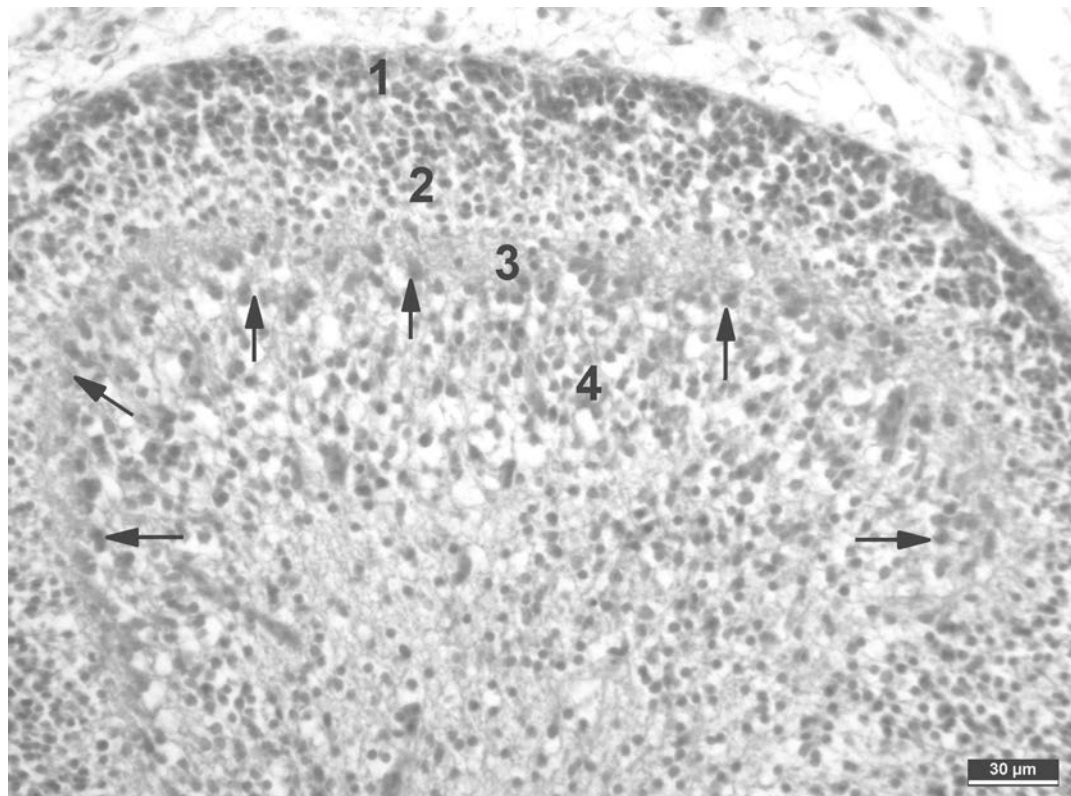


Fig. 5. – The primitive cortex of developing cerebellum on day 15 of incubation in chicken embryo. 1: External granular layer (EGL), 2: Primitive molecular layer, 3: Inner cortical layer, 4: Internal granular layer, Arrows: Future Purkinje cells. Trichrome staining.

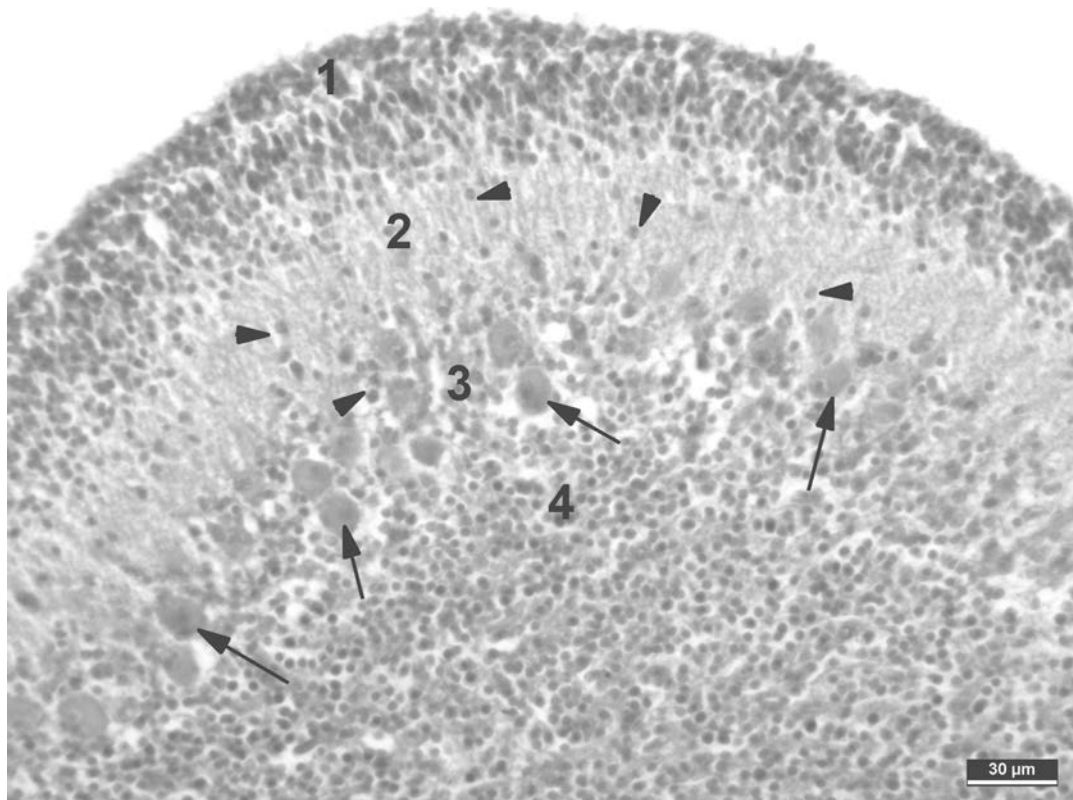


Fig. 6. – Histological sections from the cerebellum of chicken embryo on the 18th day of incubation. 1: External granular layer (EGL), 2: Molecular layer, 3: Inner cortical layer, 4: Internal granular layer, Arrows: Purkinje cells, Arrow heads: Granule cells still migrating from the EGL to the internal granular layer. Trichrome staining.

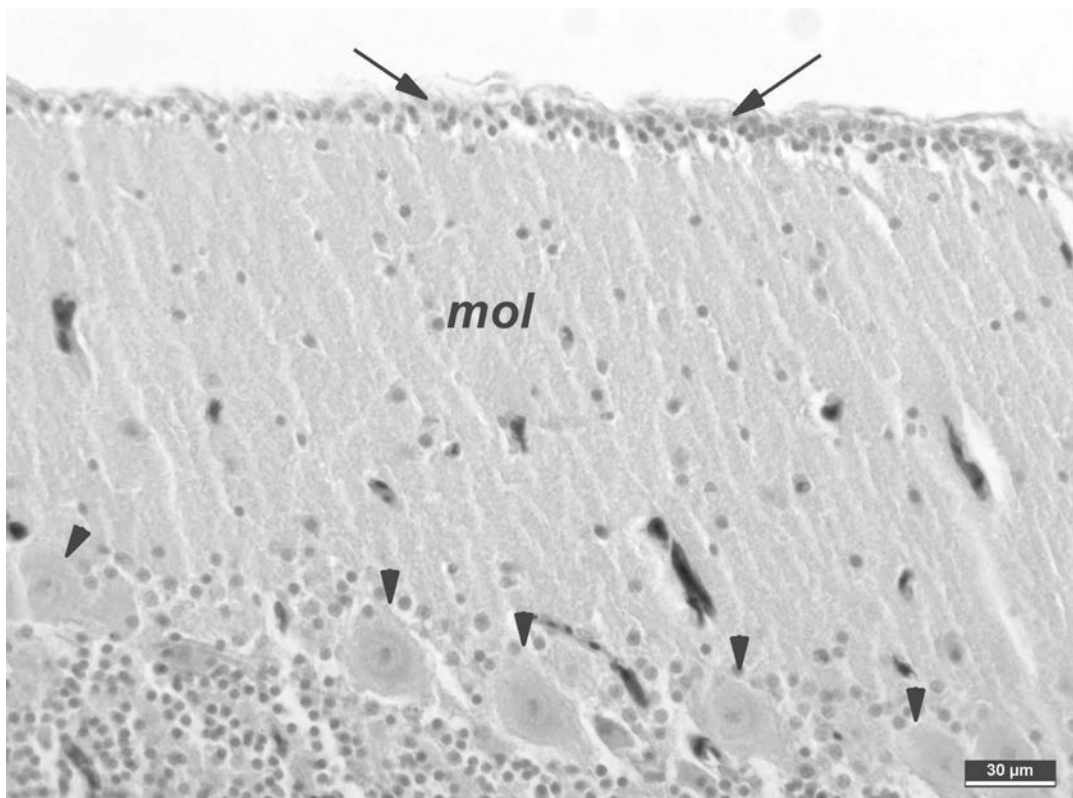


Fig. 7. – Histological sections from the cerebellum of 10-day-old chicken. The external granular layer is decreased in thickness (Arrows). mol: Molecular layer, Arrow heads: Purkinje cells arrayed in a single row. Hematoxyline and Eosin staining.

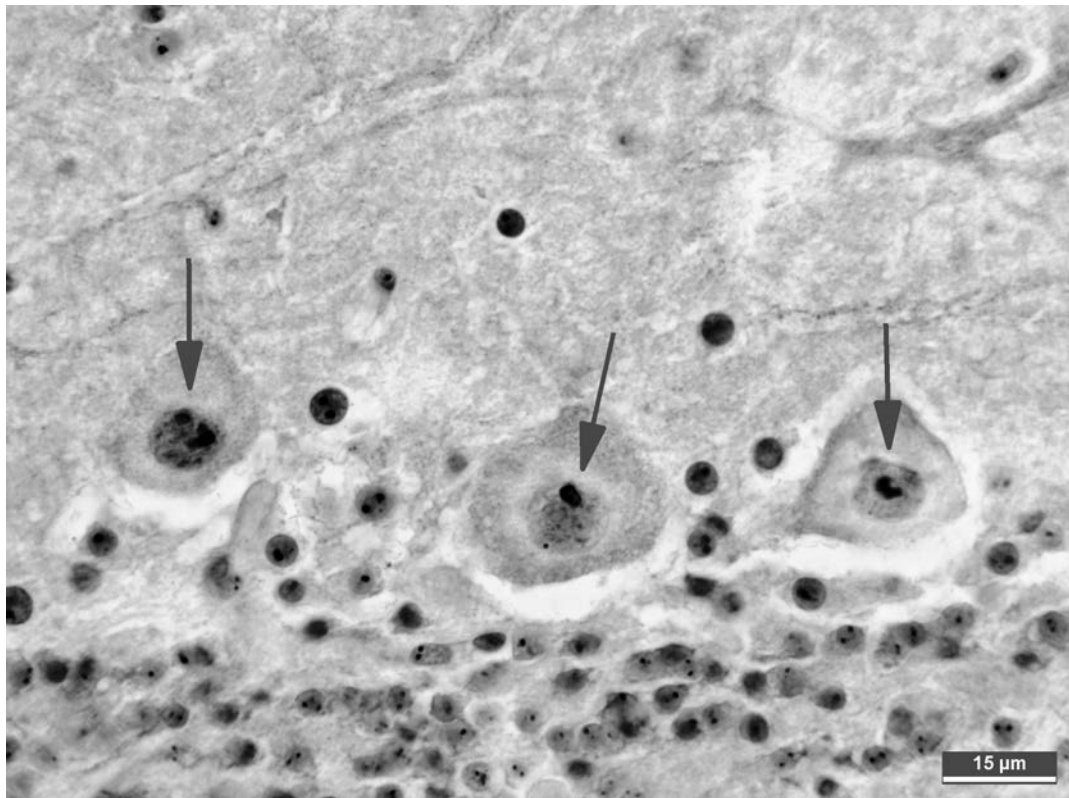


Fig. 8. – Histological sections from the cerebellum of 28-day-old chicken. Arrows: AgNORs in the nuclei of Purkinje cells. AgNOR staining.

DISCUSSION

The cerebellum differs from most of the other brain regions in that it contains two distinct germinal layers, the ventricular zone (VZ), which is most active during embryonic development, and the external granular layer (EGL), which contributes to neurogenesis after birth or hatching (FEIRABEND et al., 1985). FEIRABEND (1990) has reported that the 9th day of incubation is especially important in the histogenesis of the cerebellum, because a complete and distinctive longitudinal pattern in the arrangement of the cells of the inner mantle layer (IML) then appears for the first time. The inner cortical layer, which gives rise to the future Purkinje cells, is derived from the IML. Also in our study, the inner cortical layer was firstly recognized on the 9th day of incubation at the superficial part of the IML giving rise to the future Purkinje cells. At incubation day 9, cell accumulation was distinct in the superficial part of the outer mantle layer (EGL) (Fig. 2). This transient external layer is very important for cerebellar development because, in birds as in mammals, it produces the granule cells, which migrate through the maturing molecular and Purkinje cell layers to reach their final location in the inner granular layer (BOUVET et al., 1987). REDIES et al. (2002) found that cell raphes consist of migrating dark granule cells (Granule cell raphe) between the Purkinje cells clusters at intermediate stages of chicken embryonic development. These cells have been assumed to migrate from the EGL towards their definitive position in the inner granular layer (FEIRABEND, 1990). In

our study, these dark granule cell groups (granule cell raphe) that migrate from the EGL to the inner granular layer were observed on the 9th day of incubation (Fig. 2).

The developing cerebellum is characterised by marked folding of its surface, giving rise to closely packed transverse folds referred to as “folia” (MCGEADY et al., 2006). The primary folia are the main folia whereas the secondary folia are folia that are formed after the subfoliation of the primary folia during embryonic development of the cerebellum (FEIRABEND, 1990). Primary folia are individually numbered and secondary folia alphanumerically numbered. Differences in the number, size and morphology of the folia are associated with distinct behavioural differences (IWANIUK et al., 2006; 2007). Most comparative neuroanatomists have accepted that there are ten main folia in the avian cerebellum and the mammalian lobules I-X are homologous, respectively, with the avian folia I-X (RICHARDS, 1972). FEIRABEND (1990) reported that fissuration and foliation of the chicken cerebellar cortex have advanced on the 11-12th days of incubation. He also observed 10 primary folia and recognized the secondary foliation in folia V and IX in a mid-sagittal section through the cerebellum of a 13-day-old chicken embryo. We also observed the first cerebellar folia on the 11th day of incubation (Fig. 3) and 9 primary folia were recognized on the 13th day of incubation when a secondary foliation was just beginning in folium V (Fig. 4).

BOUVET et al. (1987) reported that the cerebellar cortex is composed of four layers at the 16th incubation day in chicken: the outer surface of the cerebellar anlage, the so-

called external germinative layer, the molecular layer, the Purkinje cell layer and the internal granular layer. In our study, the primitive cortex consisting of the external granular layer, a primitive molecular layer, an inner cortical layer and the inner granular layer were distinct a little earlier, namely on the 15th incubation day (Fig. 5).

In human cerebellum, the highest cell proliferation rate in the EGL occurs between the 28th-34th gestational weeks, and the width of the EGL remains unchanged from the 28th gestational week until the end of the first postnatal month, and it completely disappears by the 11th postnatal week (ABRAHAM et al., 2001). In chicken, BOUVET et al. (1987) observed that the EGL consists of a few persistent cells after the first week of hatching whereas the layer disappears almost completely 34 days after hatching. In our study, we observed that the EGL gradually decreased in thickness during the four weeks after hatching.

Purkinje cells arise from the ventricular neuroepithelium of the rhombencephalic alar plate (WASSEF et al., 1985) whereas granule cells originate from EGL and migrate to the inner granular layer (REDIES et al., 2002). In chickens, the majority of Purkinje cells are formed on days 3, 4 and 5 of incubation, after which Purkinje cells are arranged as longitudinal cell clusters at either side of the midline around day 9 (FEIRABEND, 1990). The Purkinje cells grow and form a single row between the molecular and the granular layers after 17 days of incubation (ESPINAR et al., 1997). BERTOSSI et al. (1986) reported that the developing Purkinje cell bodies are bipolar at first, because of two processes emerging from opposite poles of the oval cell body. They grow progressively in size and reach mean transverse diameters (mtd) in the chicken cerebellar cortex of 5.58µm, 7µm and 10.29µm on the 10th, 12th, and 14th days of incubation, respectively. BERTOSSI et al. (1986) furthermore observed that the larger (mtd: 12.30µm) Purkinje cell bodies are arranged in a single row parallel to the outline of the folium on the 16th incubation day. We found a similar pattern, namely that Purkinje cells arranged themselves in one or two rows by the 15th incubation day while on the 18th day of incubation, and they were arrayed in a manner similar to that of adult cerebellum (Figs 5-6). However, our measurements of the mtd of Purkinje cells were smaller than those of BERTOSSI et al. (1986; Table 1). Several factors may be responsible for this difference such as the image analysing programme, the numbers of embryos and Purkinje cells examined or the incubation circumstances etc.

LAFARGA et al. (1989) showed that the mean number of nucleoli per granule cell is 1.42 in rat cerebellum. We found mean AgNOR counts of the Purkinje cells of 1.35-1.54 (Table 1) which is slightly lower than the mean counts of AYDIN (2004) (1.40-1.66) in broiler and layer embryos and the average of 1.60 that LAFARGA et al. (1995) found in chicken Purkinje cells.

In our study, the nuclei of Purkinje cells and the AgNOR area increased through the entire experimental period. The mean ratio of AgNOR area to the Purkinje cell nucleus area reached its highest value on the 15th day of incubation. RUSSEL et al. (1991) reported that the occurrence of AgNORs was related to proliferative activi-

ties of the cell. However, they claimed that an increase in AgNOR cluster size rather than elevated AgNOR cluster numbers was the major feature. Ultrastructural morphology and size of the nucleolus could be sensitive indicators of cellular activity, particularly of protein synthesis (LAFARGA et al., 1989), and a relationship between transcriptional activity and cell firing rate is known (GARCIA-MORENO et al., 2000). We, therefore, propose that the relative differences that we found between the AgNOR areas might indicate different rates of protein synthesis and functional activity of the Purkinje cells.

As our results illustrate, investigating Purkinje cells as a model by applying the AgNOR technique in chicken embryo offers a good approach to the functional study of structures in the central nervous system. We hope that our findings provide reference data for future studies in this and related research topics, for example for establishing AgNOR parameters. We also hope that our data will be supplemented with other techniques such as PCNA and TUNEL in the near future.

ACKNOWLEDGEMENTS

This study forms part of the Master of Science Thesis of Serdar AKAR, for which we thank the "Selçuk University Scientific Research Projects (BAP) Coordinating Office", Project no: 06202022, for financial support.

REFERENCES

- ABRAHAM H, TORNOCZKY T, KOSZTOLANYI G & SERESS L (2001). Cell formation in the cortical layers of the developing human cerebellum. *International Journal of Developmental Neuroscience*, 19:53-62.
- AYDIN MF (2004). Yumurta ve et tavuklarının farklı dokularında gümüşleme metoduyla boyanan nükleolus organizeler (AgNOR) bölgelerinin dağılımının belirlenmesi. PhD Thesis, Selçuk University, Institute of Health Sciences, Konya.
- AYDIN MF & CELIK I (2005). Yumurta ve et tavuklarının karaciğerlerinde gümüşleme metoduyla boyanan nükleolus organizeler (AgNOR) bölgelerinin dağılımının belirlenmesi. *Veteriner Bilimleri Dergisi*, 21(1-2):91-99.
- BERTOSSI M, RONCALI L, MANCINI L, RIBATTI D & NICO B (1986). Process of differentiation of cerebellar Purkinje neurons in the chick embryo. *Anatomy and Embryology*, 175:25-34.
- BOUVET J, USSON Y & LEGRAND J (1987). Morphometric analysis of the cerebellar Purkinje cell in the developing normal and hypothyroid chick. *International Journal of Developmental Neuroscience*, 5(4):345-355.
- BUKHARI MH, NIAZI S, KHAN SA, HASHMI I, PERVEEN S & QURESHI SS (2007). Modified method of AgNOR staining for tissue and interpretation in histopathology. *International Journal of Experimental Pathology*, 88:47-53.
- CULLING CFA, ALLISON RT & BARR WT (1985). *Cellular Pathology Technique*. Butterworths and Co Ltd, London.
- ESPINAR A, PIERA V, CARMONA A & GUERRERO JM (1997). Histological changes during development of the cerebellum in the chick embryo exposed to a static magnetic field. *Bioelectromagnetics*, 18:36-46.
- FEIRABEND HKP (1990). Development of longitudinal patterns in the cerebellum of the chicken (*Gallus Domesticus*): A Cytoarchitectural study on the genesis of cerebellar modules. *European Journal of Morphology*, 28(2-4):169-223.

- FEIRABEND HKP, VANLUXENBURG EA, VANDENDEREN-Van DORP H & VOOGD J (1985). A ^3H -Thymidine autoradiographic study of the development of the cerebellum of the White Leghorn (*Gallus domesticus*): Evidence for longitudinal neuroblast generation pattern. *Acta Morphologica Neerlando-Scandinavica*, 23:115-126.
- FULTS DW, TOWLE AC, LAUDER JM & MANESS PF (1985). PP60c-src in the developing cerebellum. *Molecular and Cellular Biology*, 5(1):27-32.
- GARCIA-MORENO LM, CIMADEVILLA JM, GONZALEZ-PARDO H & ARIAS JL (2000). Functional differences between dorsal and ventral hippocampus revealed with AgNOR staining. *Psicothema*, 12(2):293-295.
- IWANIUK AN, HURD PL & WYLIE DRW (2006). The Comparative morphology of the cerebellum in Caprimulgiform birds: Evolutionary and functional implications. *Brain Behaviour and Evolution*, 67:53-68.
- IWANIUK AN, HURD PL & WYLIE DRW (2007). Comparative morphology of the avian cerebellum: II. Size of folia. *Brain Behaviour and Evolution*, 69:196-219.
- JELINEK R, PETERKA M & RYCHTER Z (1985). Chick embryotoxicity screening test—130 substances tested. *Indian Journal of Experimental Biology*, 23:588-595.
- KHANNA AK, YADAV SK, DIXIT VK & KUMAR M (2005). AgNOR count and subjective AgNOR pattern assessment (SAPA) score in carcinoma of the pancreatic head including periampullary tumors. *Journal of Pancreas*, 6(6):575-580.
- KUCERA P & BURNAND MB (1987). Routine teratogenicity test that uses chick embryos in vitro. *Teratogenesis, Carcinogenesis and Mutagenesis*, 7:427-447.
- LAFARGA M, BERCIANO MT, HERVAS JP & VILLEGAS J (1989). Nucleolar organization in granule cell neurons of the rat cerebellum. *Journal of Neurocytology*, 18:19-26.
- LAFARGA M, ANDRES MA, FERNANDEZ-VIADERO C, VILLEGAS J & BERCIANO MT (1995). Number of nucleoli and coiled bodies and distribution of fibrillar centres in differentiation of Purkinje neurons of chick and rat cerebellum. *Anatomy and Embryology*, 191(4):359-367.
- LEE A, KESSLER JD, READ TA, KAISER C, CORBEIL D & HUTNER WB (2005). Isolation of neural stem cells from the postnatal cerebellum. *Nature Neuroscience*, 8(6):723-729.
- LEE C, KIM DW, JEON GS, ROH EJ, SEO JH & WANG KC (2001). Cerebellar alteration induced by chronic hypoxia: an immunocytochemical study using a chick embryonic model. *Brain Research*, 901(1):271-276.
- MCGEADY TA, QUINN PT, FITZPATRICK ES, RYAN MT & CHALAN S (2006). Nervous System. In: MCGEADY TA, QUINN PT, FITZPATRICK ES, RYAN MT & CHALAN S (eds), *Veterinary Embryology*, Blackwell Publishing Ltd, 9600 Garsington Road, Oxford OX4 2DQ, UK:153-183.
- MIAL RC & RECKESS GZ (2002). The cerebellum and the timing of coordinated eye and hand tracking. *Brain and Cognition*, 48:212-226.
- NICKEL R, SCHUMMER A & SEIFERLE E (1977). *Anatomy of the Domestic Birds*. Paul Parey, Berlin, Hamburg, Germany.
- REDIES C, LUCKNER R & ARNDT K (2002). Granule cell raphes in the cerebellar cortex of chicken and mouse. *Brain Research Bulletin*, 57(3/4):341-343.
- RICHARDS F (1972). Morphological variation in the cerebellum of the Passerine Family Icteridae. Master of Thesis, Faculty of Texas Tech University.
- ROBERT-FORTELE I, JUNERA HR, GERAUD G & HERNANDEZ-VERDUN D (1993). Three-dimensional organization of the ribosomal genes and Ag-NOR proteins during interphase and mitosis in PtK1 cells studied by confocal microscopy. *Chromosoma*, 102:146-157.
- RUSSEL DL, ALISO MR & SARRAF C (1991). Variations in the occurrence of silver-staining nucleolar organizer regions (AgNORs) in non-proliferating and proliferating tissues. *Journal of Pathology*, 165:43-51.
- SUR E, CELIK I, OZNURLU Y, AYDIN MF, SEN I. & OZPARLAK H (2003). Enzyme histochemistry and AgNOR numbers in the peripheral blood leukocytes of 6 month-old Kangal bred Anatolian shepherd dogs. *Revue De Médecine. Vétérinaire*, 154(10):591-598.
- TEKIN ME (2003). Örneklerle bilgisayarda istatistik. S.Ü.Veteriner Fakültesi Yayın Ünitesi, Konya.
- VOOGD J & GLICKSTEIN M (1998). The Anatomy of the Cerebellum. *Trends in Cognition Science*, 21:370-375.
- WASSEF M, ZANETTA JP, BREHIER A & SOTELO C (1985). Transient biochemical compartmentalization of Purkinje cells during early cerebellar development. *Developmental Biology*, 111:129-137.

Received: December 26, 2008

Accepted: July 12, 2010

Branch editor: Huybrechts Roger